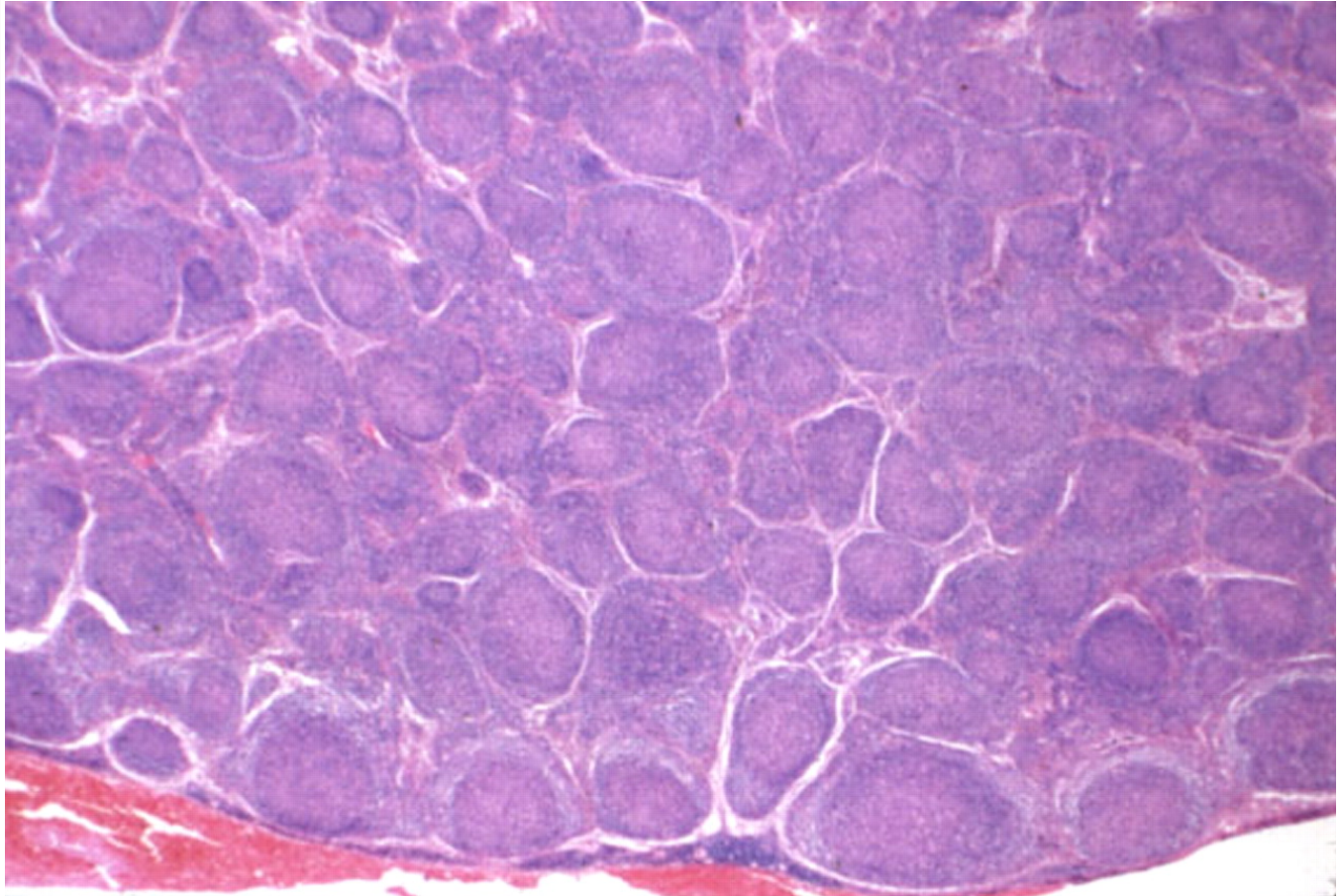
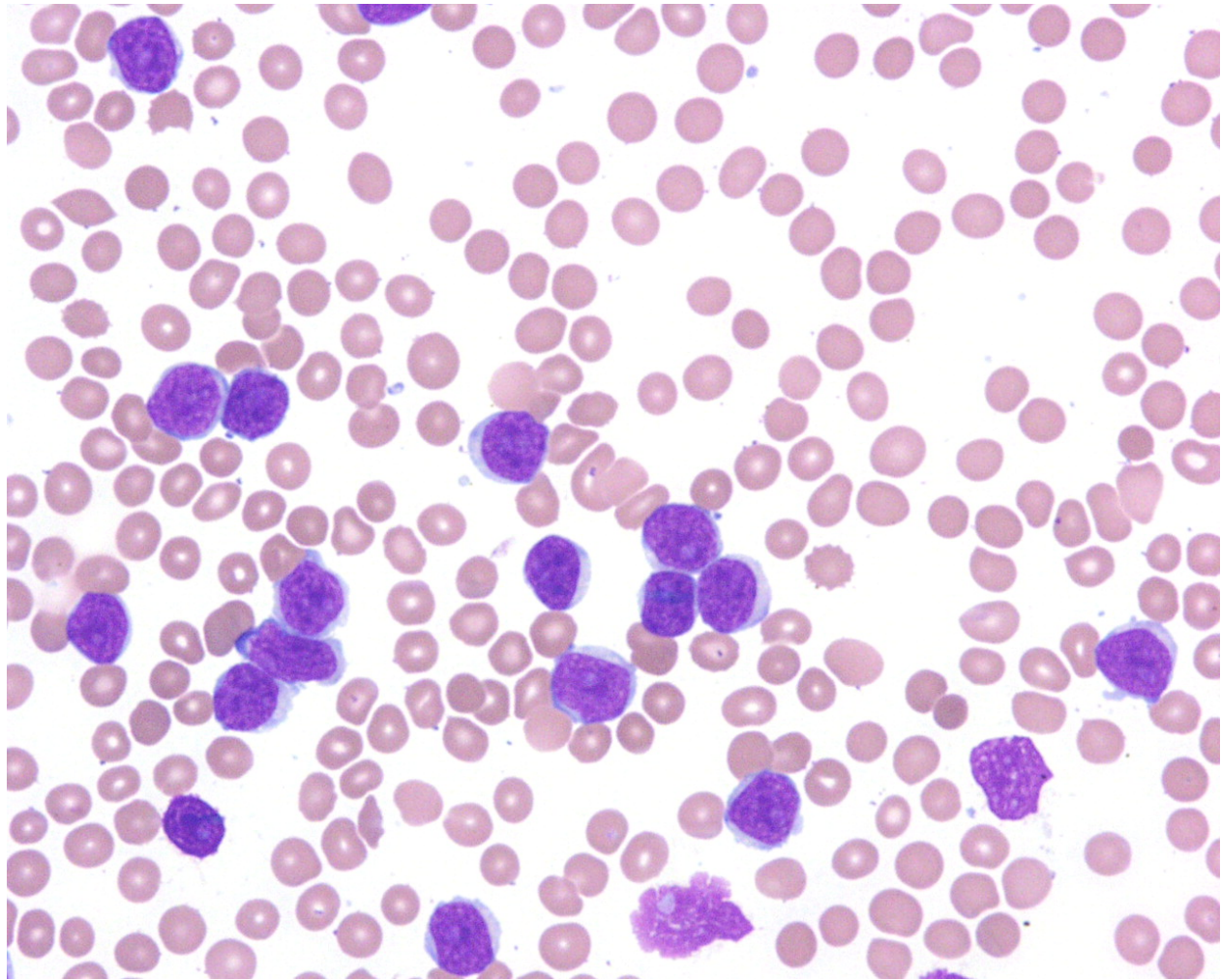


Follicular Lymphoma - 1.



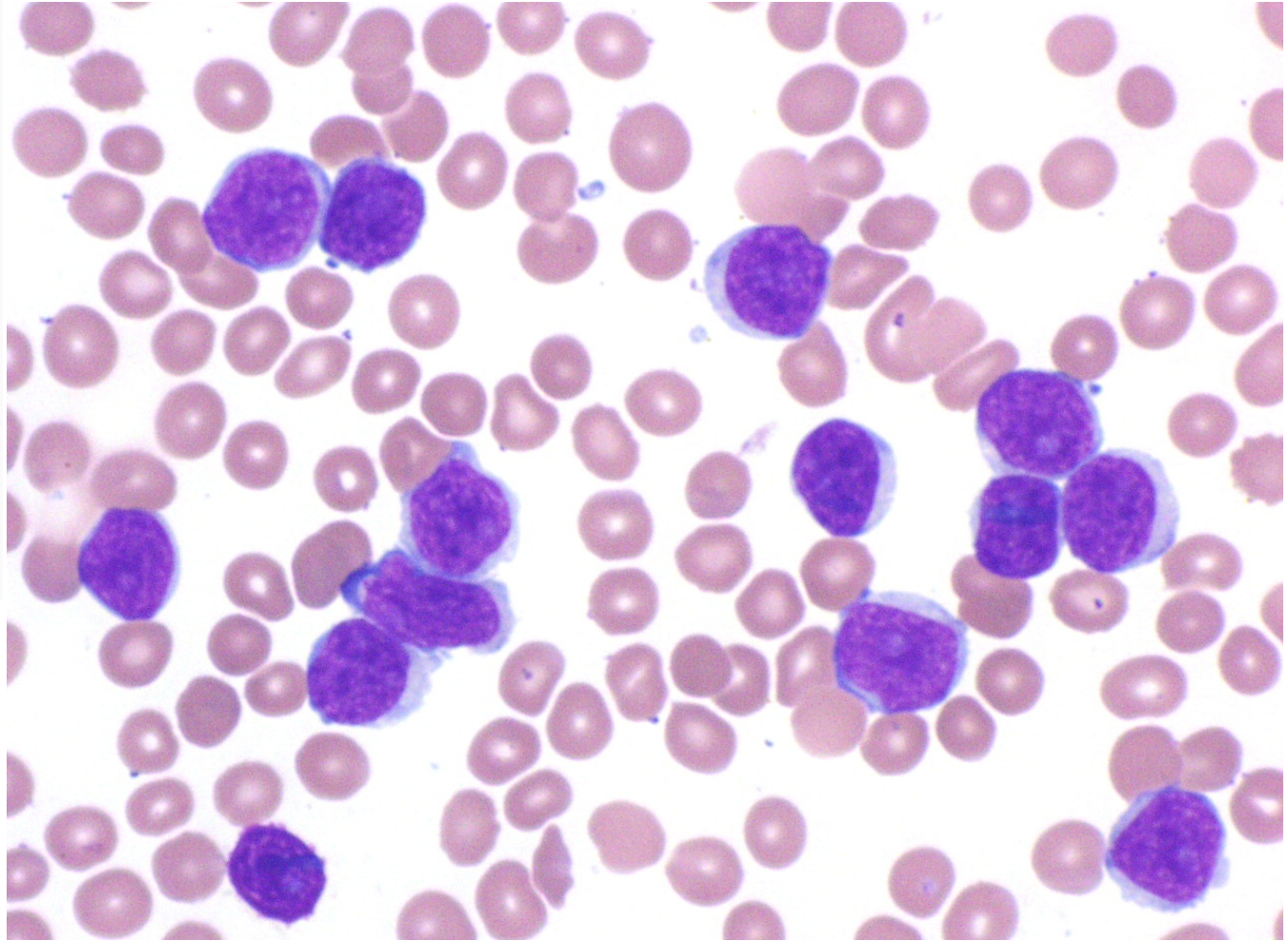
Marshall Kadin, ASH Image Bank 2011; 2011-2050

Peripheralizing Follicular Lymphoma with Atypical Morphology - 1.



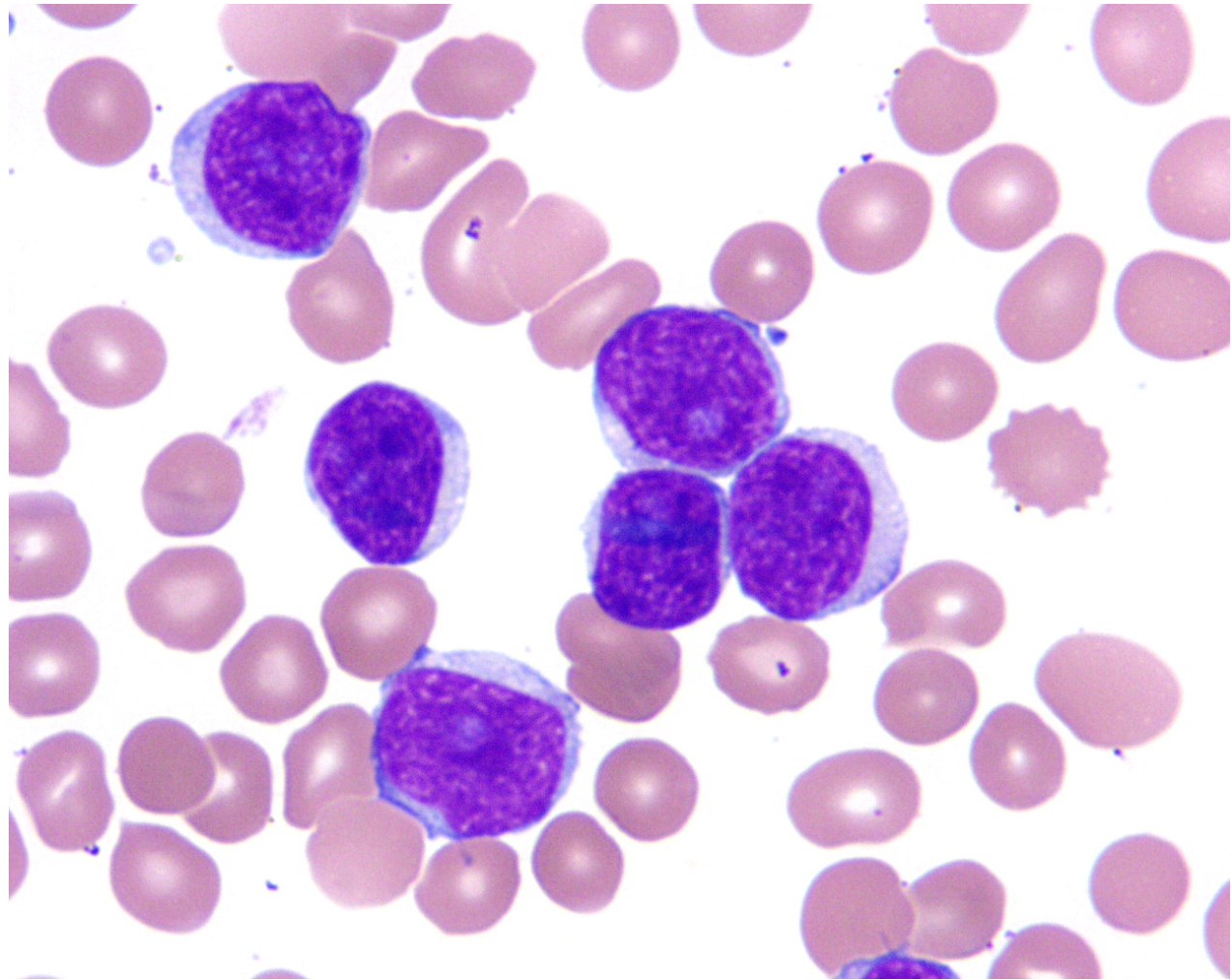
John Lazarchick, ASH Image Bank 2013; 2013-3427

Peripheralizing Follicular Lymphoma with Atypical Morphology - 2.



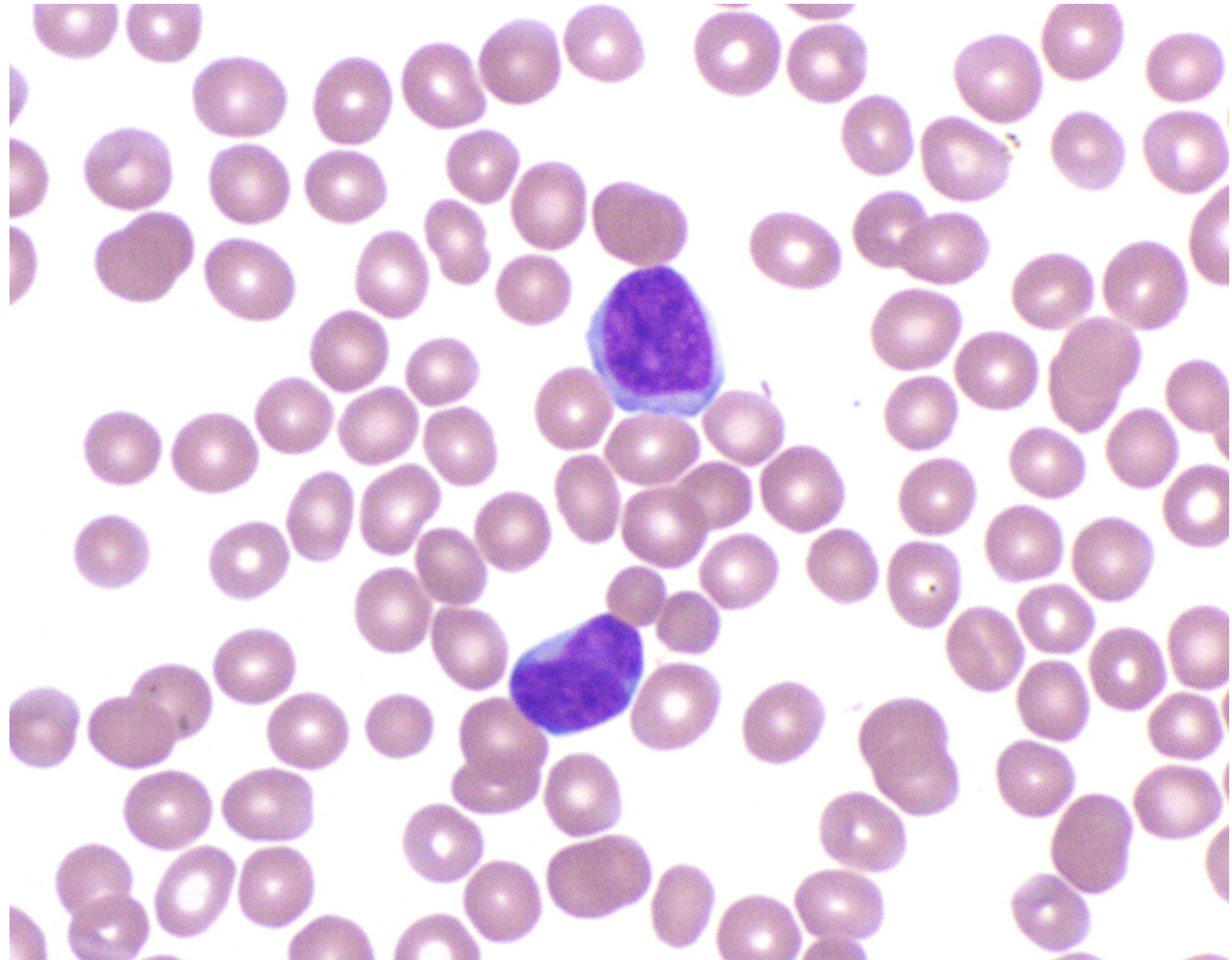
John Lazarchick, ASH Image Bank 2011; 2011-3428

Peripheralizing Follicular Lymphoma with Atypical Morphology - 3.



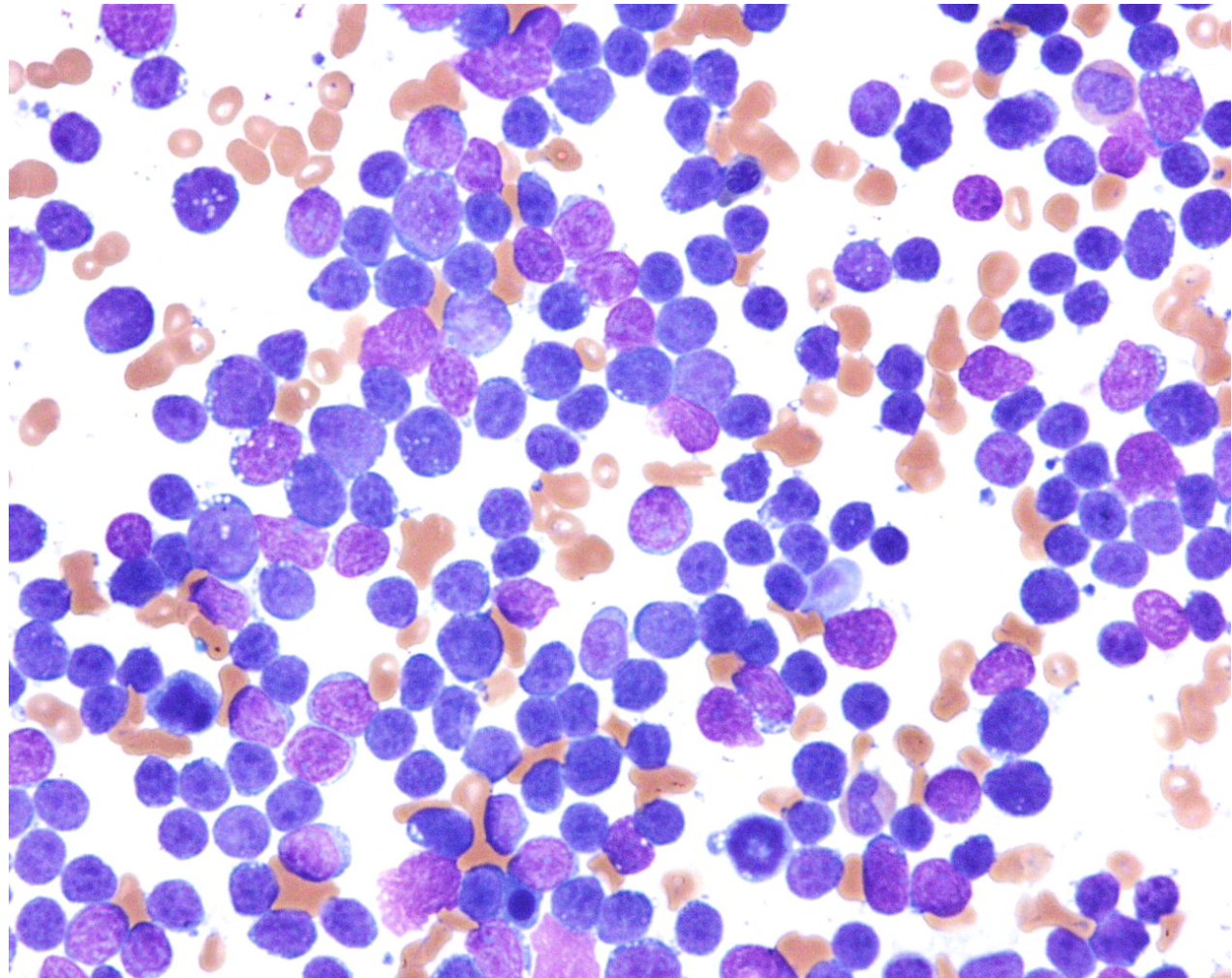
John Lazarchick, ASH Image Bank 2011; 2011-3429

Peripheralizing Follicular Lymphoma with Atypical Morphology - 4.



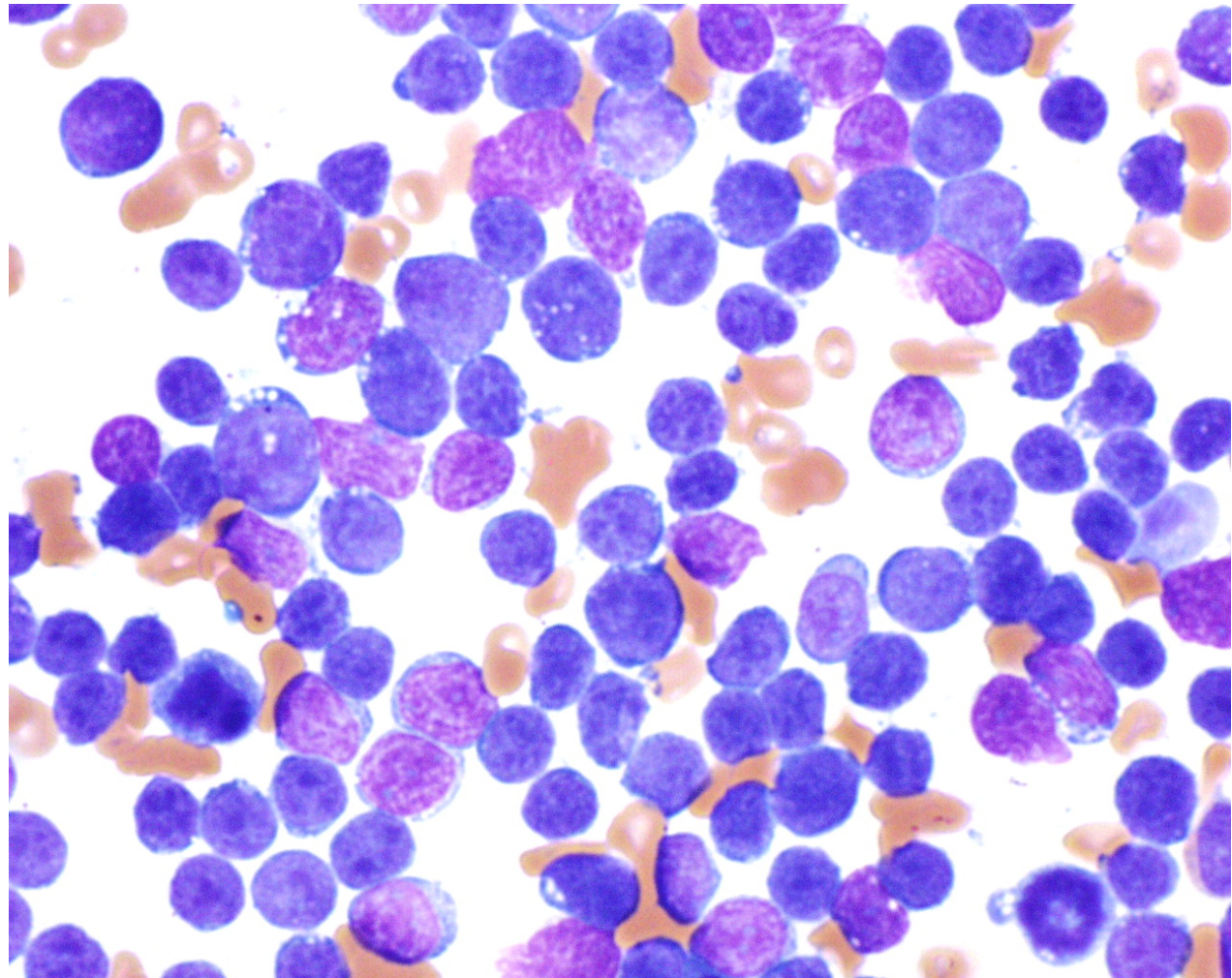
John Lazarchick, ASH Image Bank 2013; 2013-3430

Peripheralizing Follicular Lymphoma with Atypical Morphology - 5.



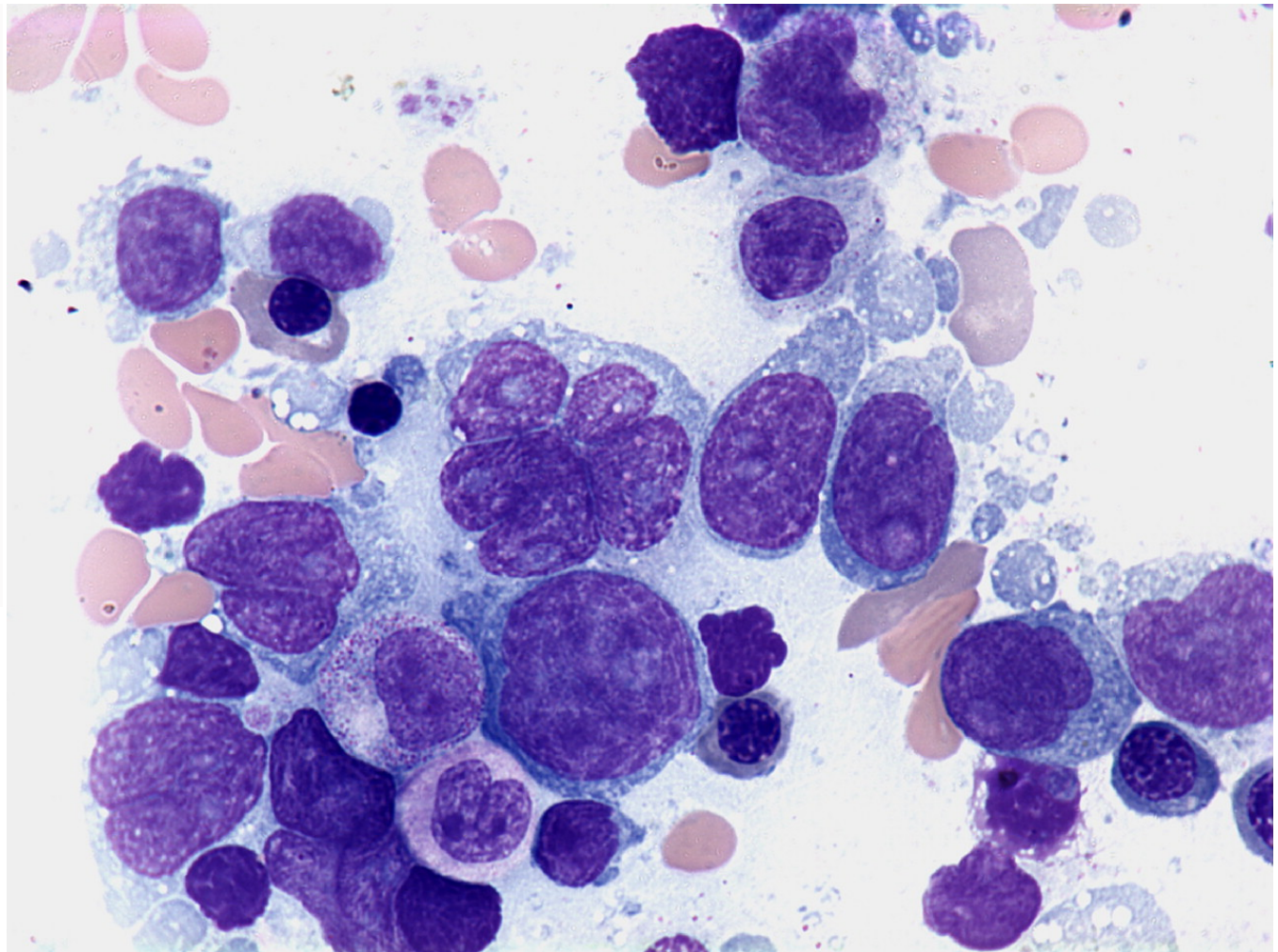
John Lazarchick, ASH Image Bank 2011; 2011-3431

Peripheralizing Follicular Lymphoma with Atypical Morphology - 6.



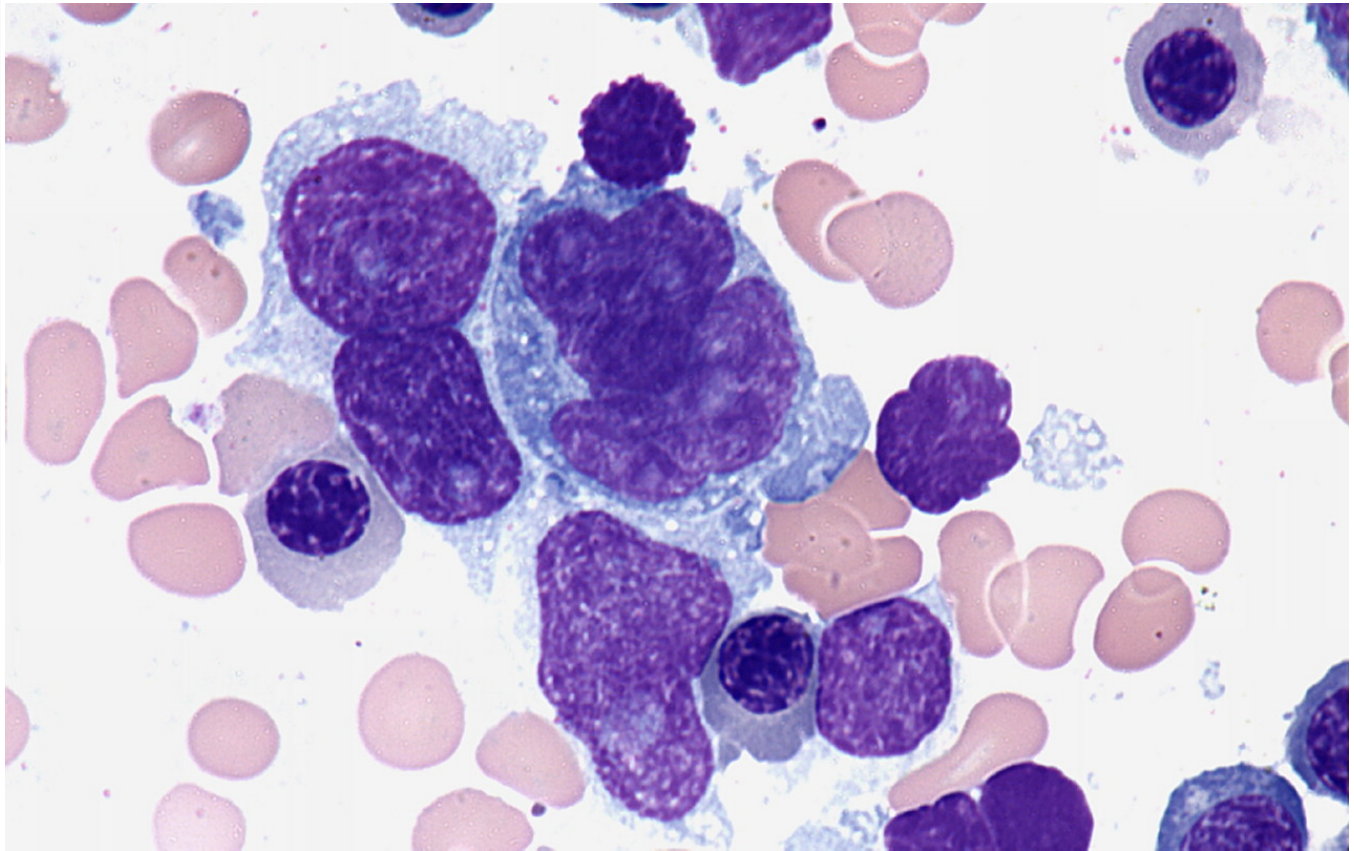
John Lazarchick, ASH Image Bank 2011; 2011-3432

Diffuse large B-cell lymphoma - bone marrow aspirate - 1.



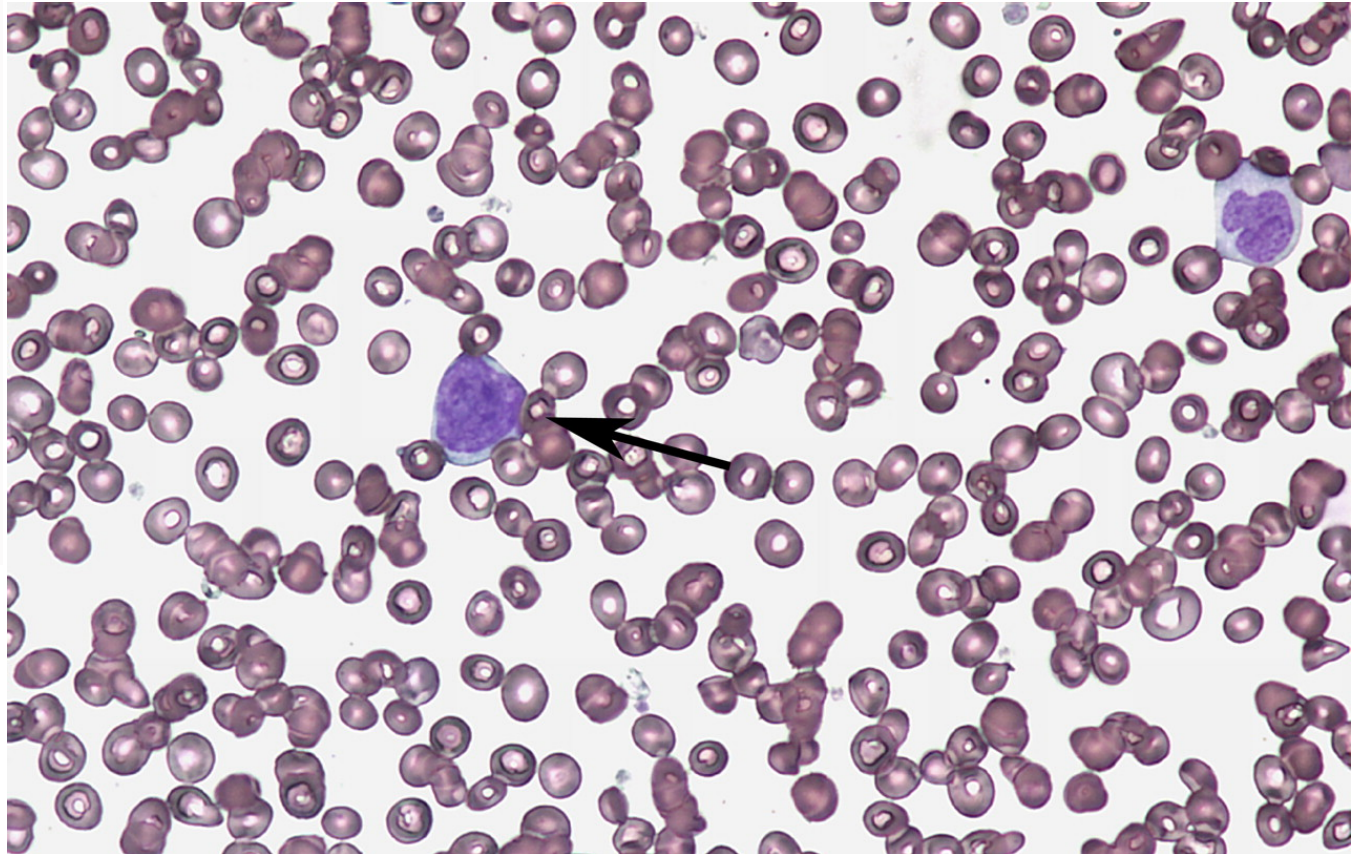
Peter Maslak, ASH Image Bank 2011; 2011-3860

Diffuse large B-cell lymphoma - bone marrow aspirate - 2.



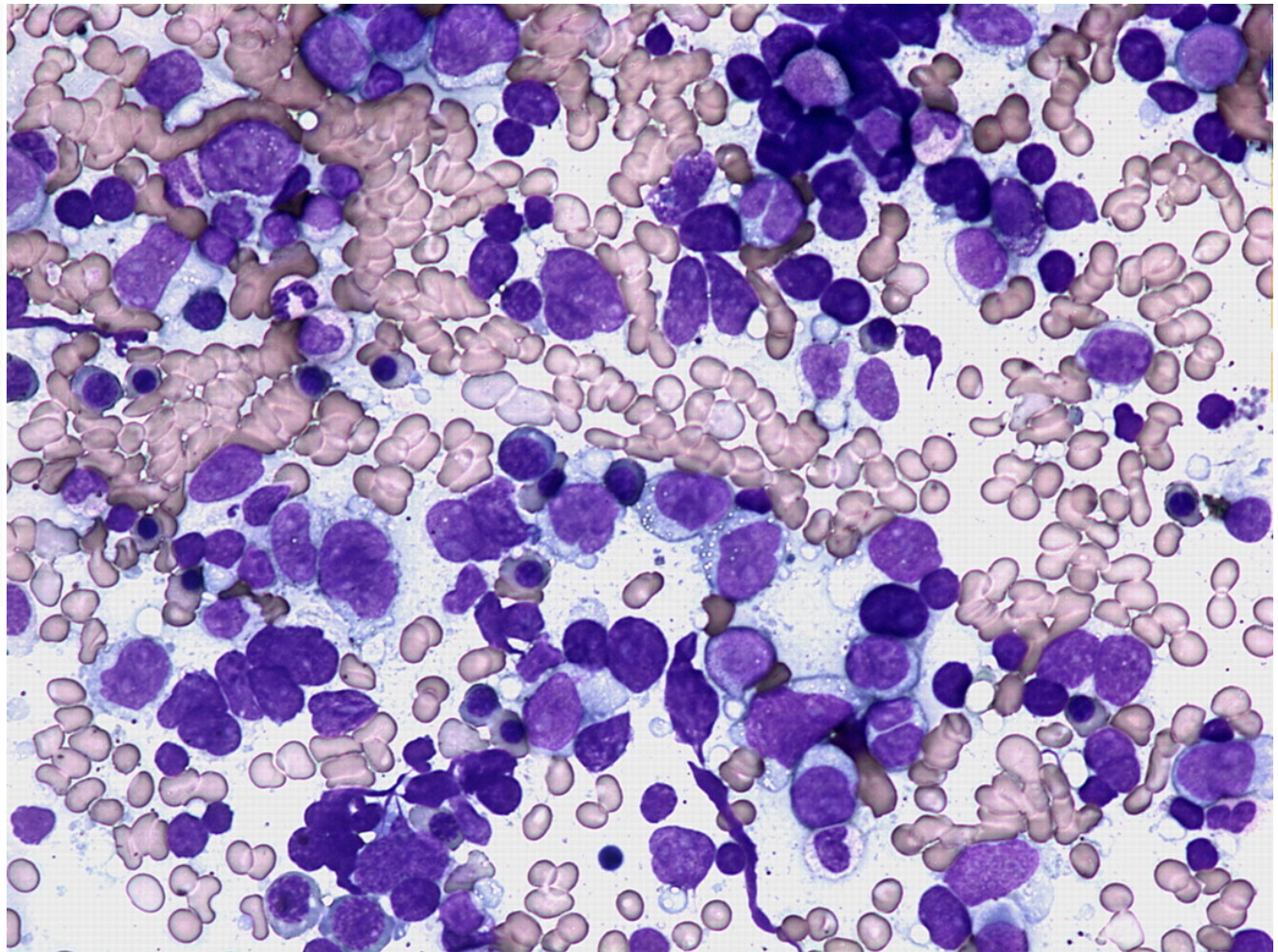
Peter Maslak, ASH Image Bank 2011; 2011-3861

Diffuse large B-cell lymphoma - bone marrow aspirate - 3.



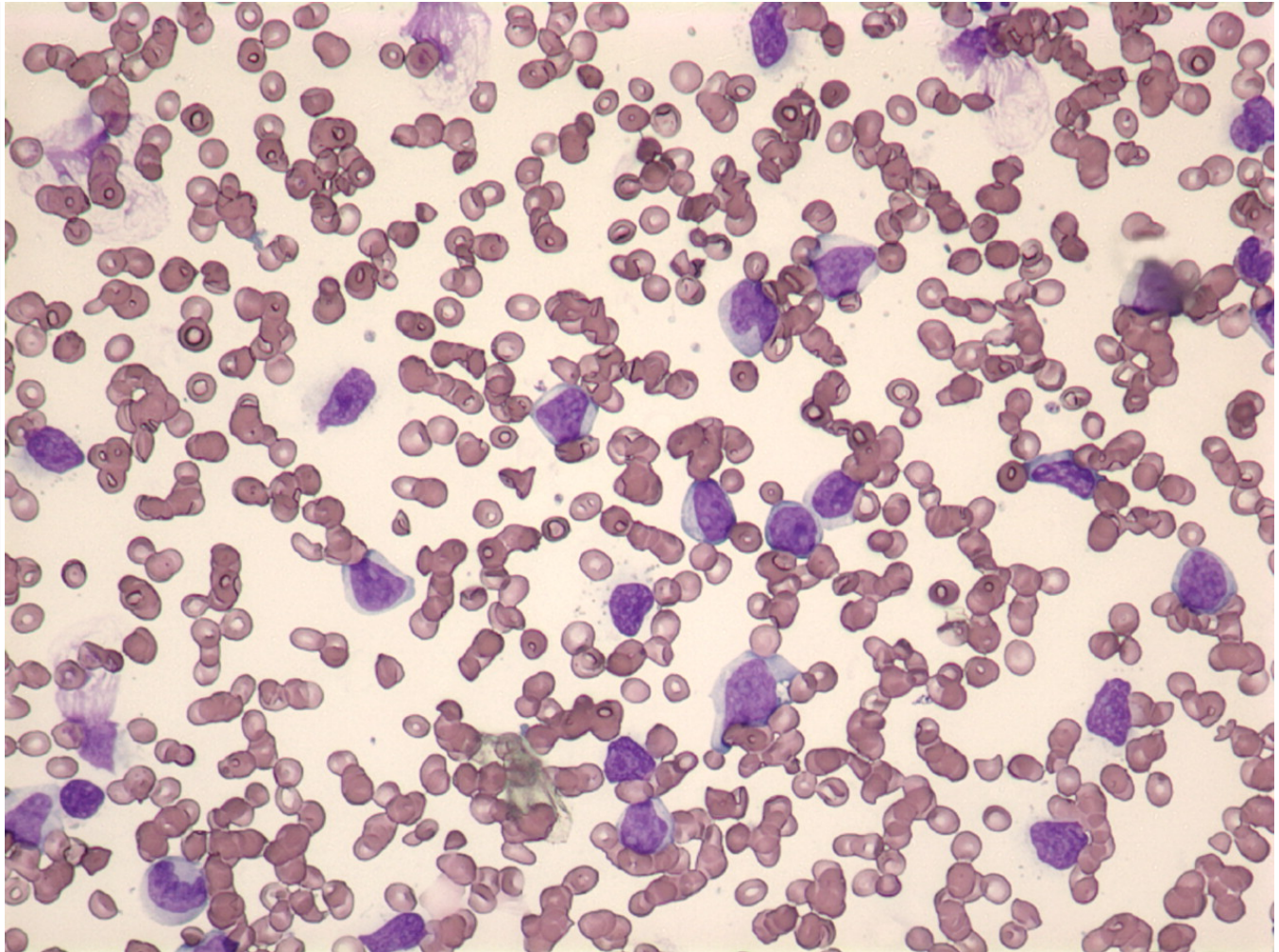
Peter Maslak, ASH Image Bank 2011; 2011-3862

Diffuse large B-cell lymphoma - bone marrow aspirate - 4.



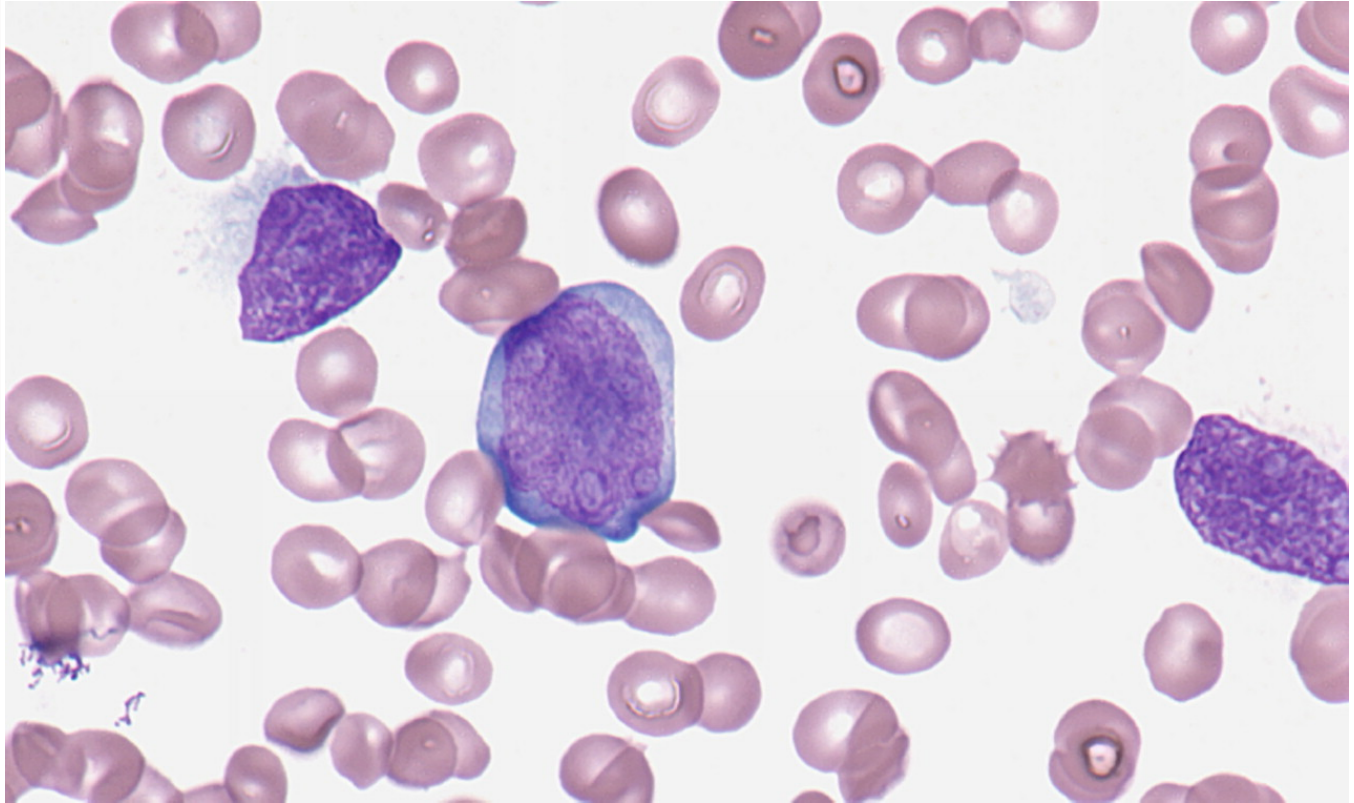
Peter Maslak, ASH Image Bank 2013; 2013-3863

Leukemic phase of large cell lymphoma - 1.



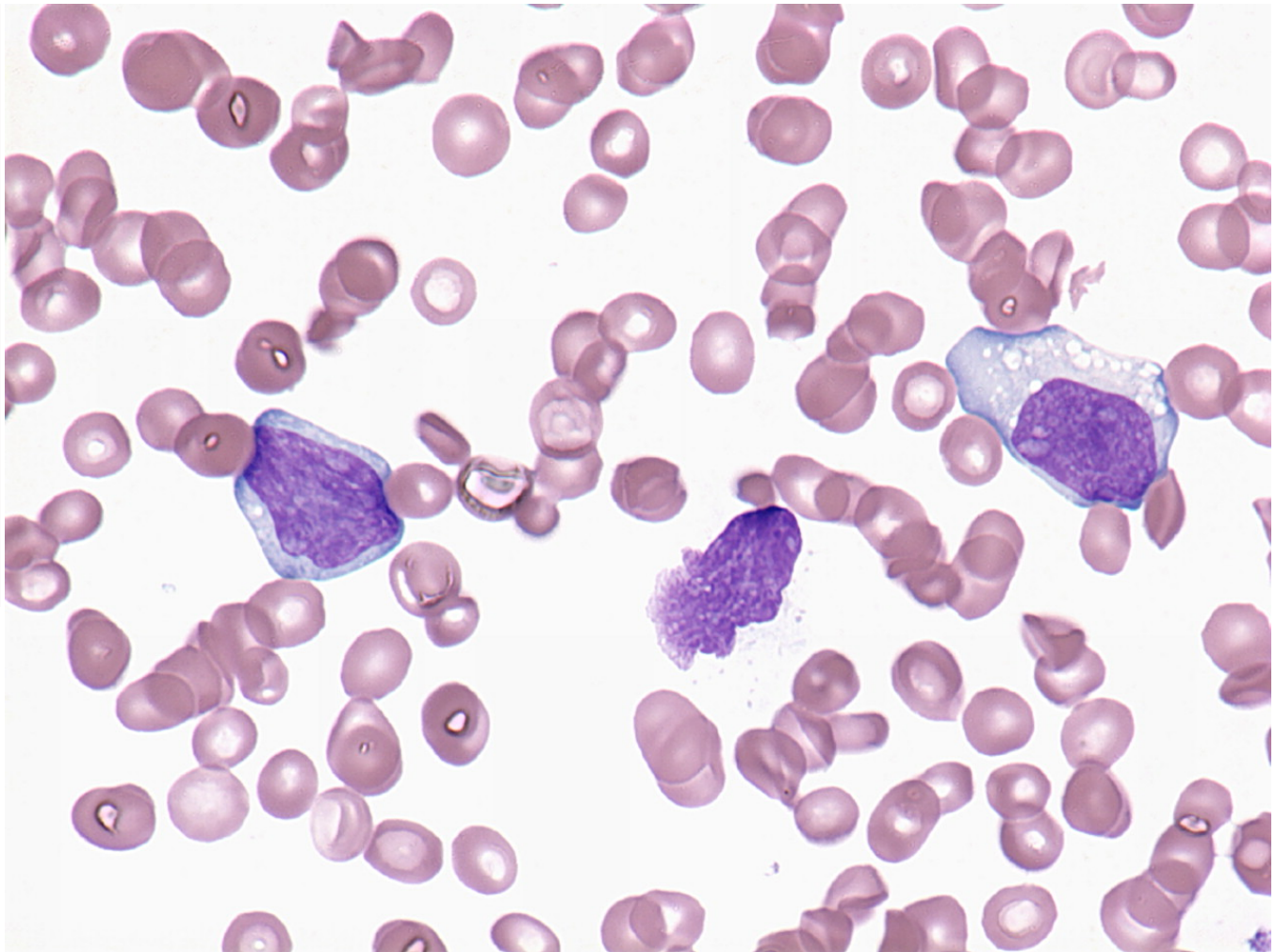
Peter Maslak, ASH Image Bank 2011; 2011-3905

Leukemic phase of large cell lymphoma - 2.



Peter Maslak, ASH Image Bank 2011; 2011-3906

Leukemic phase of large cell lymphoma - 3.

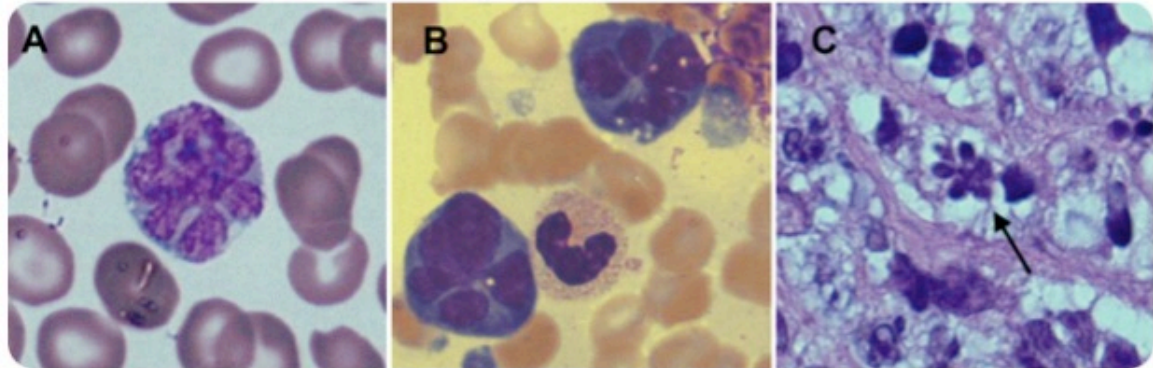


Peter Maslak, ASH Image Bank 2013; 2013-3907

Diffuse large B-cell lymphoma in leukemic phase with flower cell morphology



A 76-year-old man presented with right shoulder pain, weight loss, and night sweats.



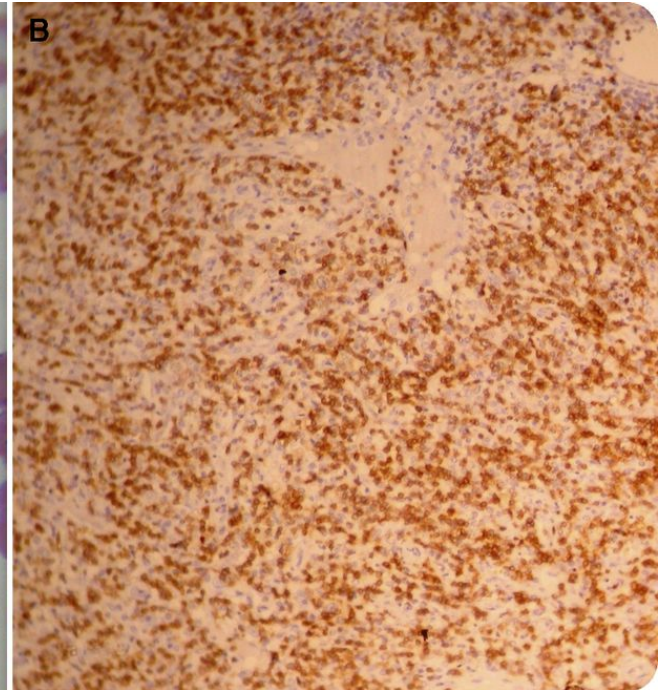
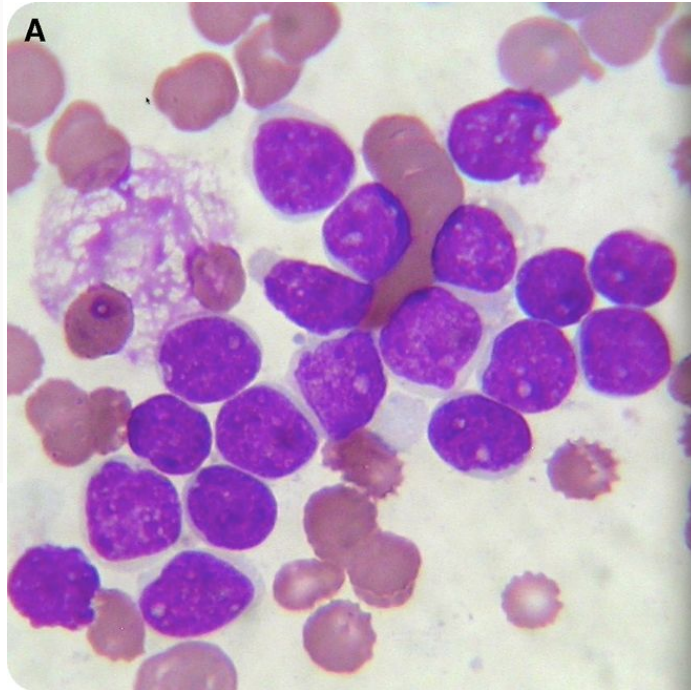
Wong E , and Juneja S Blood 2014;123:3378

©2014 by American Society of Hematology



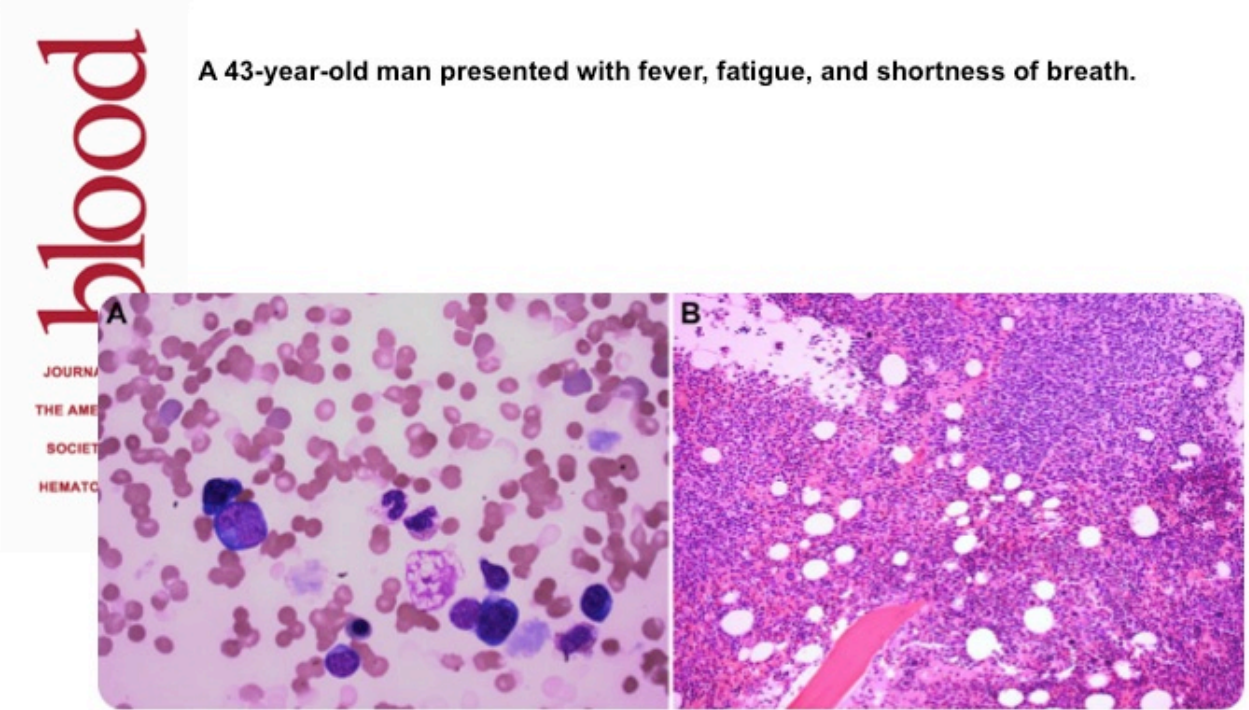Eric Wong and Surender Juneja, ASH Image Bank 2014; 2014-28649

Diffuse large B-cell lymphoma in leukemic phase with flower cell morphology



Biswadip Hazarika, ASH Image Bank 2014; 2014-30588

Atypical lymphocytosis, cold agglutinin hemolytic anemia, and monoclonal gammopathy in an HIV patient with marrow involvement by diffuse large B-cell lymphoma



A 43-year-old man presented with fever, fatigue, and shortness of breath.

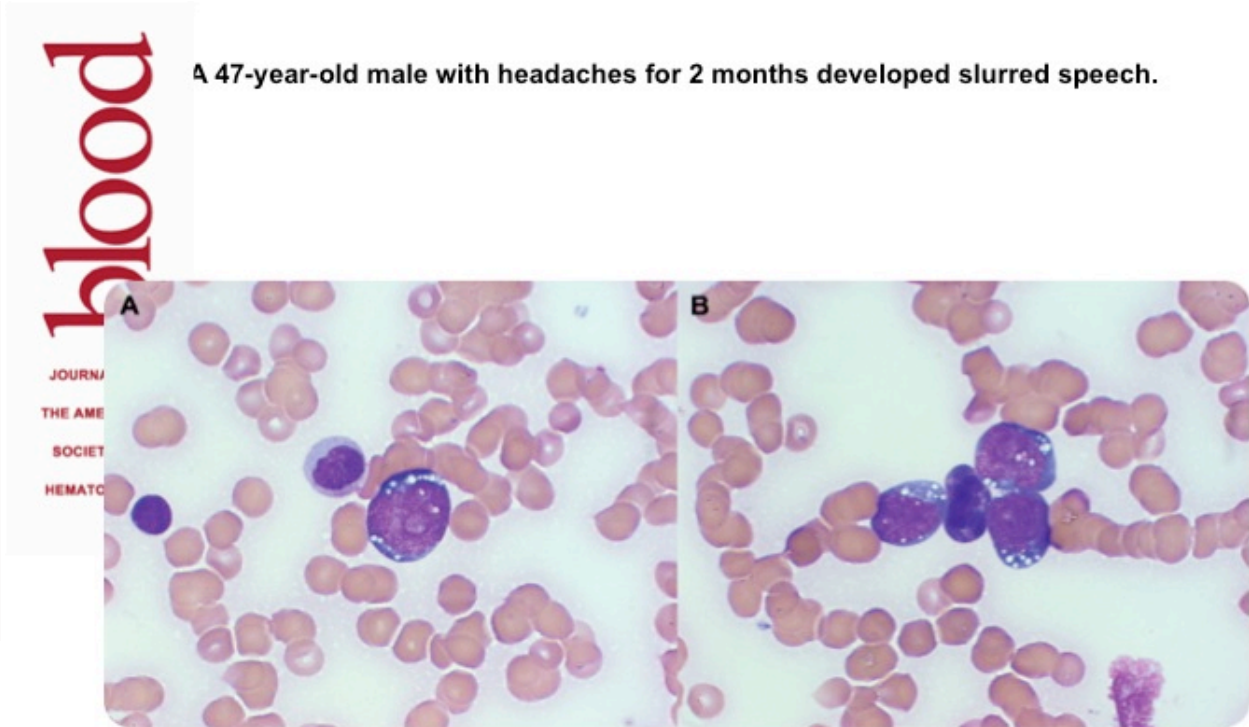Chen M , and Abedi M Blood 2013;122:3711

©2013 by American Society of Hematology

Mingyi Chen and Mehrdad Abedi, ASH Image Bank 2013; 2013-23525



Burkitt lymphoma-leukemic phase



A 47-year-old male with headaches for 2 months developed slurred speech.

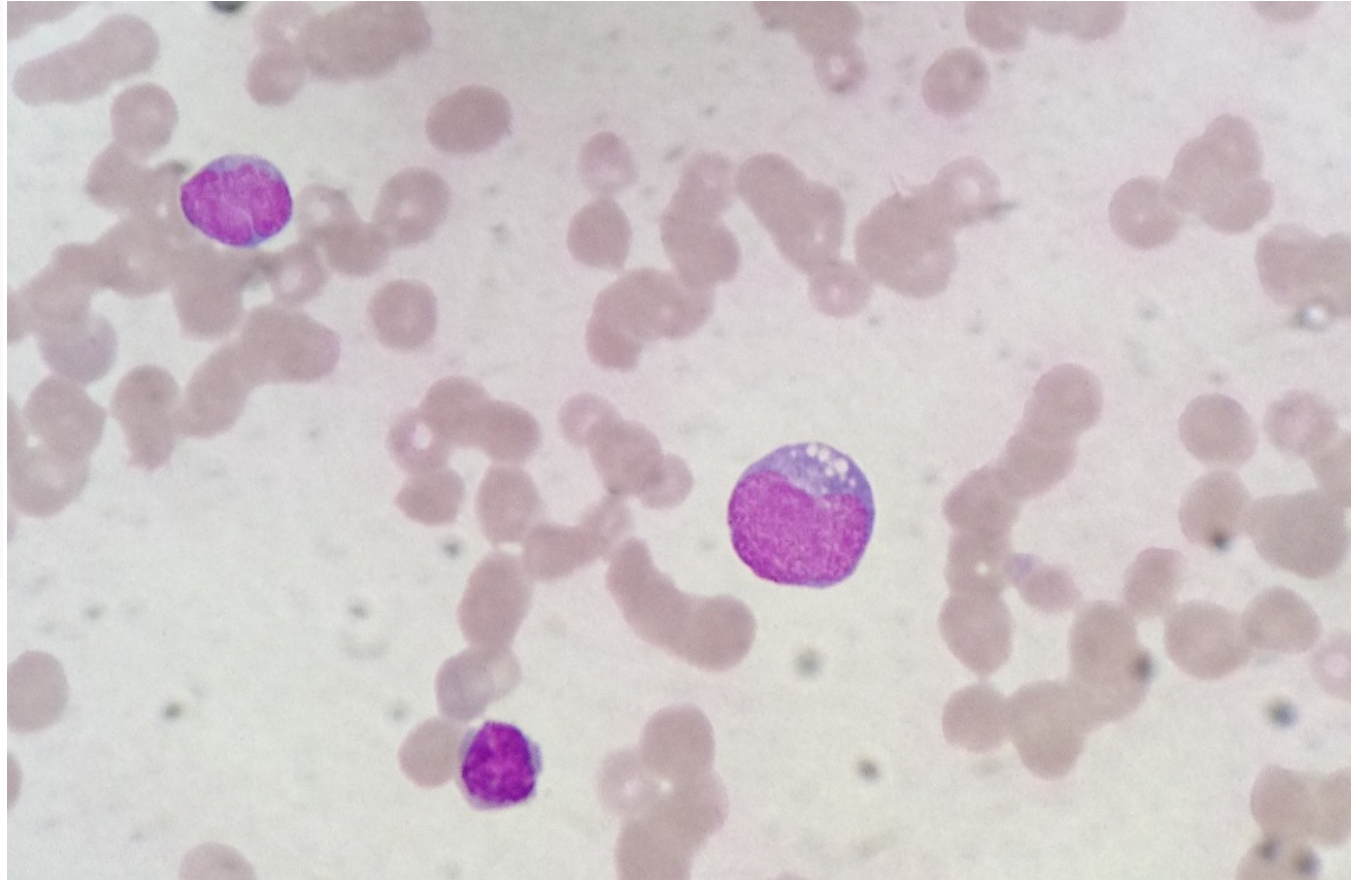
Munoz J , Barthel B Blood 2012;120:247-247

©2012 by American Society of Hematology

Blood Work B Munoz and B Barthel, ASH Image Bank 2012; 2012-12564

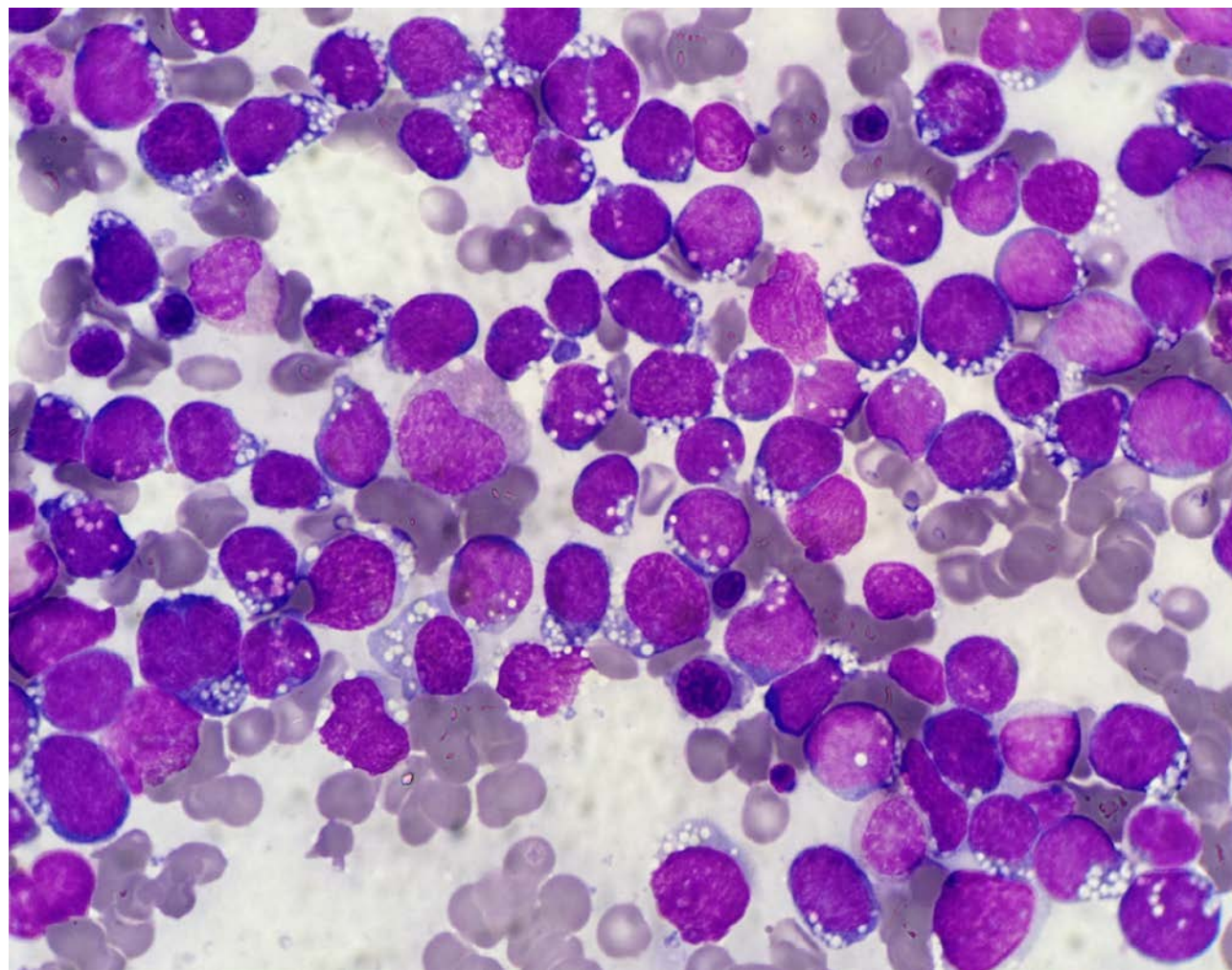


Burkitt lymphoma cells in peripheral smear.Leishman(1000X)



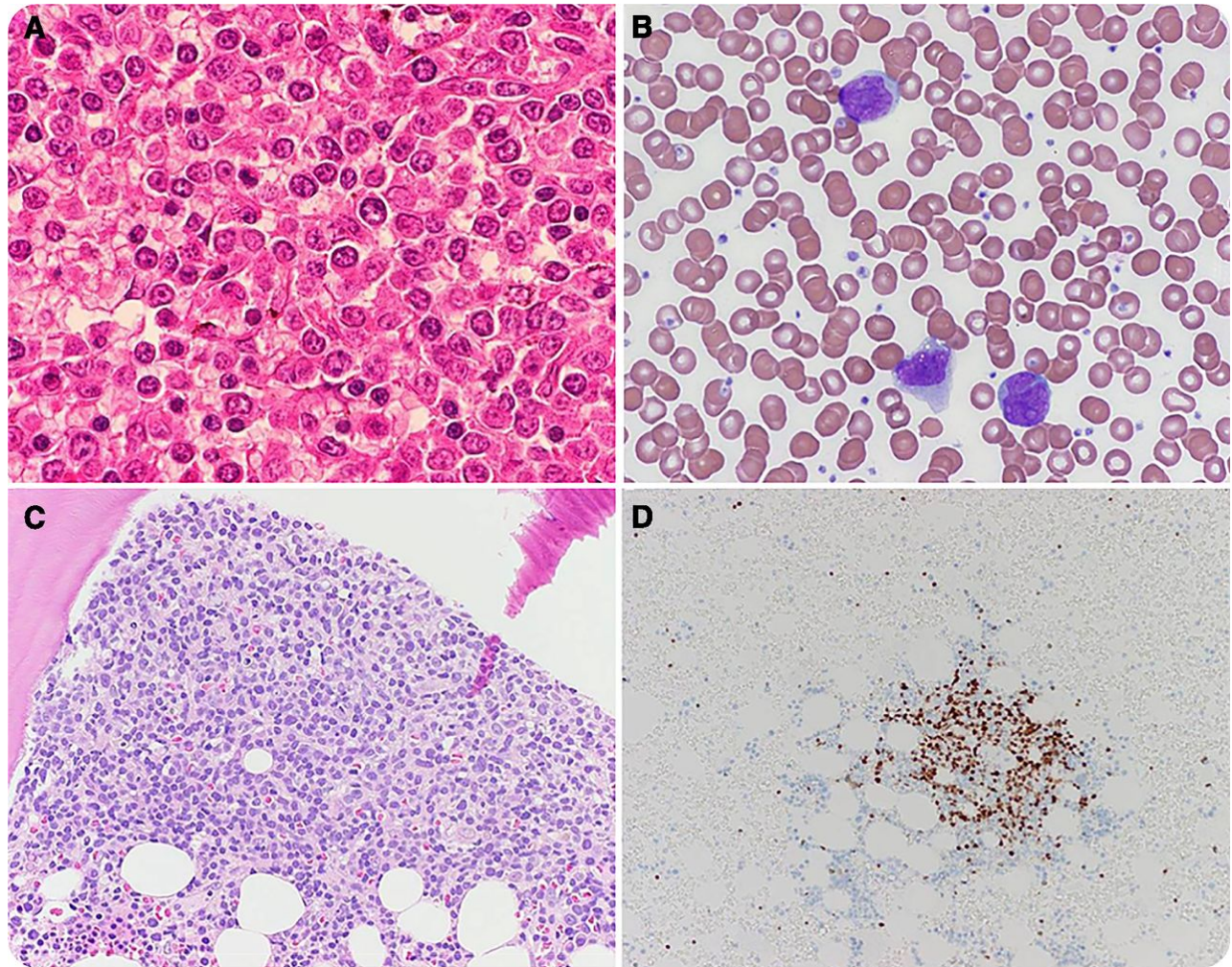
Anupama Arya,Dilip Kumar,Poonam Das, ASH Image Bank 2014; 2014-29106

Burkitt Lymphoma cells infiltrating Bone Marrow.(MGG,1000X)



Anupama Arya,Dilip Kumar,Poonam Das, ASH Image Bank 2014; 2014-29108

Spontaneous splenic rupture in mantle cell lymphoma with leukemic variant



Shahzad Raza and Donald C. Doll, ASH Image Bank 2014; 2014-29315